



**PATIENT**

Buster Thurin

**PRESENTING CLINICAL SIGNS**

History: Friday exam - increased resp effort. Not eating well. Started on clavacillin and pred pending lab results - on Friday LAB: BNP 1700, ALT 528, Low SG 1015 - called owner and she said that today he is having a harder time breathing

**SPECIES**

Canine

**RADIOGRAPHIC FINDINGS** \*NOTE: Images submitted for supplemental cardiac information only. Cardiomegaly with LA dilation. Cranioventral infiltrate. Equivocal for concurrent CHF.

**BREED**

Havanese

**ECHOCARDIOGRAM FINDINGS**

2D, m-mode, color flow and doppler imaging is available. The mitral valve is diffusely thickened with significant prolapse into the left atrial lumen. There is severe eccentric mitral regurgitation present. The MR velocity is normal. There is severe left atrial enlargement. There is mild left ventricular dilation. Left ventricular systolic function is hyperdynamic. No right atrial or ventricular dilation (subjective). Mild thickening of the tricuspid valve with noTR. There is normal systolic flow velocity across the aortic valve. The aortic valve appears trileaflet with normal mobility. The main pulmonary artery is normal in diameter. The pulmonic valve is normal in appearance. No pericardial/pleural effusion or cardiac masses are seen.

**SEX**

Male Neutered

**AGE**

15 years

**CARDIAC CHART**

**WEIGHT**

11.2lbs

**INTERPRETED BY**

Maggie Machen  
Lamy, DVM, DACVIM  
(Cardiology)

CANINE CARDIAC PARAMETERS	MR VMAX (m/s)	TR VMAX (m/s)	LA/AO (Boon method)	LA/AO (Heart Base; Swe)	FS (%)	EF (%)	EPSS (cm)
NORMAL PARAMETER	4.5-5.5	<2.7	1.3	<1.6	28-40	40-100	<0.6
PATIENT	4.6	NA	2.2	2.3	57	90	NM
CANINE CARDIAC PARAMETERS	HR (BPM)	AV VMAX (m/s)	PV MAX (m/s)	BODY WEIGHT (kg)	LA 2D short axis Base view (cm)	LVIDd Avg; 2D and m-mode short axis (cm)	LVIDs Avg; 2D and m-mode short axis (cm)
NORMAL PARAMETER	50-100	0.7-1.7	0.7-1.6	BELOW	BELOW	BELOW	BELOW
PATIENT	88	0.9	0.6	5.1	3.0	3.2	1.7
*Normal chamber parameters expressed as a mean value (SD)				3	1.27 (5.3)	2.46 (2.46)	1.36 (5.5)
<b>BODY WEIGHT DEPENDENT PARAMETERS</b>				5	1.40 (4.5)	2.74 (5.2)	1.60 (4.7)
*Note: All measurements based upon multi-modal images and methods. An average value is reported.				10	1.50 (3.8)	3.27 (3.5)	2.06 (3.1)
				15	1.83 (2.0)	3.71 (2.4)	2.43 (2.1)
				20	2.02 (1.9)	4.14 (2.2)	2.80 (2.0)
				25	2.18 (2.4)	4.48 (2.9)	3.10 (2.5)
				30	2.33 (3.3)	4.83 (3.9)	3.39 (3.4)
				35	2.48 (4.3)	5.17 (5.0)	3.69 (4.5)
				40	2.62 (5.2)	5.48 (6.1)	3.96 (5.4)
				50	2.88 (7.1)	6.07 (8.3)	4.46 (7.4)

**IMAGING PERFORMED BY**

Fred Gromalak, DVM

**HOSPITAL NAME**

SVS Imaging

**REFERRING VET**

Dr. Miller

**INVOICE**

28347

**DATE**

1/16/23

**INTERPRETATION OF THE FINDINGS & FURTHER RECOMMENDATIONS**

The cause of the murmur is chronic degenerative valve disease causing severe mitral regurgitation. Severe left atrial enlargement indicates the risk for spontaneous congestive heart failure is elevated. No additional issues such as systolic dysfunction are identified.

The described cough/dyspnea is likely multi-factorial in origin, including a mechanical component



## PATIENT

Buster Thurin

## SPECIES

Canine

## BREED

Havanese

## SEX

Male Neutered

## AGE

15 years

## WEIGHT

11.2lbs

## INTERPRETED BY

Maggie Machen Lamy, DVM, DACVIM  
(Cardiology)

## IMAGING PERFORMED BY

Fred Gromalak, DVM

## HOSPITAL NAME

SVS Imaging

## REFERRING VET

Dr. Miller

## INVOICE

28347

## DATE

1/16/23

due to cardiomegaly, possible concurrent airway disease/pneumonia and/or early CHF given the severity of disease. Screening chest radiographs are equivocal with some concern for a primary respiratory component. Highly recommend a Radiologist evaluation; however, given the symptoms and echo findings full lifelong **cardiac support is recommended as below** including Lasix therapy. Depending on clinical response to the medications, cough suppression may also be useful. **Monitoring of sleeping breathing rates in the future will be paramount to determine the origin of any future cough.** The average survival of canine patients with active pulmonary edema is 8-9 months on medications; however, they generally are able to maintain a good quality of life for that period. Patient will always be at risk for recurrent CHF, development of arrhythmias/LA tear, syncope and/or sudden death in the future. Monitoring of renal values is recommended lifelong.

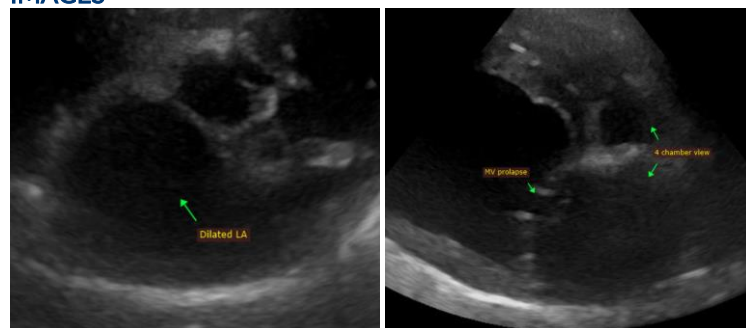
Omega fatty acid supplementation and mild salt restriction may also be of some long term benefit. Monitor for development of a worsening cough, labored breathing, exercise intolerance or collapse episodes.

Plan: Screening BP is recommended. **Suggest a Radiologist review of the films.** Administer Pimobendan 0.3mg/kg PO q12h. Administer low dose furosemide/Lasix 1 mg/kg PO q12h. Administer spironolactone 1-2mg/kg PO q12h. Consider hydrocodone with homatropine (0.2-0.4mg/kg PO up to q4-6 hours PRN) if cough persists despite normal SRRs. Continue antibiotic coverage such as Baytril to cover respiratory bases.

A renal panel and BP are recommended in 10-14 days, then every 3-4 months on diuretics to ensure tolerance of medications. If doing well at that time and BP >130mmHg, institute ACEI 0.5mg/kg PO q12h.

A recheck echocardiogram is recommended in 6 months to screen for progression, sooner if clinical signs arise/persist.

## IMAGES



The information and recommendations provided are based on the images presented by the referring veterinarian. No evaluation can be communicated regarding pathology that was not visible in the image/video clips provided.

Thank you for this referral. This report was generated using transcription software, and minor dictation errors may be present. If the clinical or image interpretation does not parallel your findings or if I can be of any further assistance, please contact me.

Maggie Machen Lamy, DVM



**PATIENT**

Buster Thurin

Diplomate of the American College of Veterinary Internal Medicine (Cardiology)

info@sonopath.com

**SPECIES**

Canine

**BREED**

Havanese

**SEX**

Male Neutered

**AGE**

15 years

**WEIGHT**

11.2lbs

**INTERPRETED BY**

Maggie Machen  
Lamy, DVM, DACVIM  
(Cardiology)

**IMAGING  
PERFORMED BY**

Fred Gromalak, DVM

**HOSPITAL NAME**

SVS Imaging

**REFERRING VET**

Dr. Miller

**INVOICE**

28347

**DATE**

1/16/23